

A Clinical Study In The Treatment And Management Of Chronic Fissure In Ano

Kavya P¹, Dr. Suresh Kotwal²

¹Student, KBN University, Department of General Surgery, Kalaburagi, India.
Kavya88@gmail.com

²Professor, KBN University, Department of General Surgery, Kalaburagi, India.

ABSTRACT

In the course of standard clinical practice, anal fissures are often observed. Surgical closure of anal fissures has long been the standard of care. More cautious methods of therapy have emerged as a consequence of advances in pharmacological knowledge of the internal anal sphincter. Topical 2% Diltiazem gel is compared in this research for its symptomatic alleviation, healing potential, and adverse effects.

Individuals who have symptoms of ano-fissure for a duration exceeding six weeks will be classified as having chronic ano-fissure and will be included in a randomized trial for comparison purposes.

Our research found that out of 100 patients, 76 (76.0%) were treated conservatively with local application diltiazem gel and had a full recovery from their fissure. Among these patients, 74 (97.4%) reported no adverse effects and just 2 (92.6%) reported experiencing them. After undergoing lateral sphincterotomy, 24 patients (24.0%) were able to achieve a full recovery.

When dealing with chronic fissure in the nose, topical diltiazem should be thought of as the first line of therapy. Only individuals who have had a recurrence after previous pharmaceutical therapy has failed should undergo an internal sphincterotomy.

Keywords: Anal fissure, sphincterotomy, diltiazem.

I. INTRODUCTION

In the outpatient department, anal fissures are often seen by surgeons. The vast majority of these illnesses are rather minor and will usually go away on their own. However, chronic state will develop in a subset of patients. There will be at least one or two instances on the normal surgical list. Patients will have to endure terrible outcomes due to complications from the surgery for this ailment, even though it is easily treatable. If the patient does not get treatment promptly, he will experience anguish due to his symptoms.

A longitudinal rip or fissure in the anal canal's skin is called an anal fissure. While most superficial fissures, known as acute fissures, heal on their own within a few weeks, deeper anal fissures may take considerably longer to mend. It is possible to diagnose chronic fissure if an anal fissure does not heal after six weeks. The definition provided by an amorphological description is more exact. At the base of the chronic anal fissure, you can see the internal sphincter muscle fibers, and the borders of the fissure are thickened. On the lower end of the fissure, you can see an external skin tag called the sentinel pile. On the higher end, you might see a hypertrophied papilla. The growth of fibrotic connective tissue is the source of certain aspects of fissure chronicity, which are related to chronic infection.

Traditional locations for chronic fissures include the posterior midline (6 o'clock position) and the anterior midline (1% of men and 10% of females, respectively). Additional pathologies, such as syphilis, TB, inflammatory bowel disease, or immunosuppressive disorders like human immunodeficiency virus, can be indicated by fissures that do not appear at the 6 o'clock position or by the presence of several fissures. Although anybody may develop chronic anal fissures, those in their youth and general health are at increased risk. Equally, it affects men and women.

OBJECTIVES

1. The efficacy, risks, side effects, and length of hospital stay of 2% Diltiazem Gel applied locally against lateral sphincterotomy for comparison.

II. REVIEW OF LITERATURE

When the bottom portion of the anal canal develops a linear ulcer, it is called an anal fissure. If cracks appear between three and six weeks after symptoms begin, they are considered acute. Acute anal fissures often develop as a result of trauma sustained after passing a hard stool or, less frequently, when passing diarrhea many times. Near the posterior midline, you'll find 95% of men's fissures and 5% near the anterior midline; in contrast, roughly 80% of women's fissures will be found posteriorly and 20% near the anterior midline.

Among the most prevalent symptoms of ano is a ripping or searing pain during defecating. The development of fissure in ano is believed to be caused by a vicious cycle of pain, spasm, and ischemia, which the therapy aims to interrupt.

Diltiazem, whether used topically or taken orally, has also been used to treat fissures; it's possible that it has less adverse effects than topical nitrates.

When applied topically, Diltiazem and Bethanechol both significantly lower pressure in the anal sphincter and repair fissures just as well as nitrates, but with none of the negative side effects. When nitroglycerine fails to seal a fissure, topical diltiazem may restore healing in 48% to 75% of cases. Common surgical techniques for anal fissures include anal stretch, as well as open and closed lateral sphincterotomies, posterior midline sphincterotomies, and, to a lesser degree, dermal flap covering. For many doctors, lateral sphincterotomy is still the gold standard, researchers from Egypt's Tanta University's Department of General Surgery compared surgical medical sphincterotomy with other methods for treating persistent fissures in the anus. Concludes With few problems and no recurrence, lateral internal sphincterotomy is a simple and effective procedure. No special preparation is necessary for a medical sphincterotomy, and the risks are minimal. You can undo its effects. It is usual to relapse after that. Patients who are unable or unwilling to have surgery should consider this as a viable alternative before the procedure.

In adults, the effectiveness of 2% topical diltiazem hydrochloride was not substantially different from topical glyceryltrinitrate, according to the Cochrane review and two other RCTs; nevertheless, there is some evidence that it reduces the frequency of headaches. Another randomized controlled trial established no statistically significant difference between botulinum toxin injection and 2% topical diltiazem hydrochloride in terms of effectiveness. Statistical analysis was not conducted in two further randomized controlled trials, although their results imply that topical diltiazem was not as beneficial as surgical sphincterotomy. Compared to 0.2% topical glyceryltrinitrate, 2% topical diltiazem hydrochloride was more efficacious in a small randomized controlled trial including children 0-12 years old. Due to differences in research methodology, demographics, and follow-up, the studies' estimations of fracture healing and recurrence rates differed substantially.

The effectiveness of diltiazem in treating fissures that did not respond to nitroglycerine was examined in a research published by Jonas et al. 24. One hour before and one hour after applying diltiazem gel (700 mg of 2% concentration) to the distal anal canal, anal manometry was performed on a consecutive set of 39 patients (median age 42 years) who had chronic anal fissures that did not close after therapy with nitroglycerine ointment (0.2%). For eight weeks, the gel was used twice a day. Every 15 days, we tracked the healing of the fissures and any adverse effects.

In only 8 weeks, 49% of patients saw fissure healing after using topical diltiazem gel, which reduced resting anal pressure by 20%. Diltiazem helped 44% of patients become well, while 69% had previously taken nitroglycerine for the whole 8 weeks. Headaches caused some individuals to stop taking nitroglycerine too soon. Ten percent of those on diltiazem had unwanted symptoms such tiredness, headache, perianal itching, and mood disturbances.

An additional research used the topical administration of 2% diltiazem gel (equivalent to 8 mg) three times day to diltiazem patients. Twelve female patients (mean age 45 years) presented with a median history of fissures of six months. In 39% of patients, they were linked to a sentinel tag. The percentage of patients whose fissures healed was 48%; this included 75% of those whose fissures had not healed after using glyceryltrinitrate ointment. At three months, there were no side effects and no recurrences.

III. METHODOLOGY

A. DEFINITION OF STUDY SUBJECT

Chronic fissure in the nose is defined as the presence of symptoms for more than six weeks; patients exhibiting these symptoms will be included in a randomized trial for comparative evaluation.

B. INCLUSION CRITERIA

Male and female patients aged 15 to 80 years old, as well as those undergoing surgery and those hospitalized with

fissure in ano syndrome.

C. EXCLUSION CRITERIA

1. Mentally handicapped patients
2. Recurrent fissures
3. Fissures with hemorrhoids and fistula
4. Fissure associated with malignancies
5. Fissure secondary to specific diseases like Tuberculosis, Crohn's disease etc.
6. Pregnant women
7. Patients with cardiac problems
8. Patients with immunocompromised state

One group of patients had lateral sphincterotomy, whereas the other received local administration of 2% diltiazem gel.

D. STATISTICAL ANALYSIS USED:

Descriptive statistics
Chi square test
Contingency table analysis SPSS version 25.0

E. Follow up for a minimum of 3 months.

F. With the goal of contrasting the local administration of 2% diltiazem gel with lateral sphincterotomy in terms of:

1. Effectiveness
2. Hospital stay
3. Complications
4. Side effects

H. STUDY DESIGN

A clinical trial including at least 100 individuals for comparison.

I. DURATION OF STUDY

March 2021 to November 2022

J. Place of Study:

Faculty of Medical Science Khaja Bandanawaz University

IV. RESULTS

RESULTS AND ANALYSIS:

TABLE NO. 1 GENDER WISE DISTRIBUTION OF PATIENTS

PATIENTS	MALES	FEMALES
100	54	46

Of the 100 patients included in our research, 54 were men and 46 were girls.

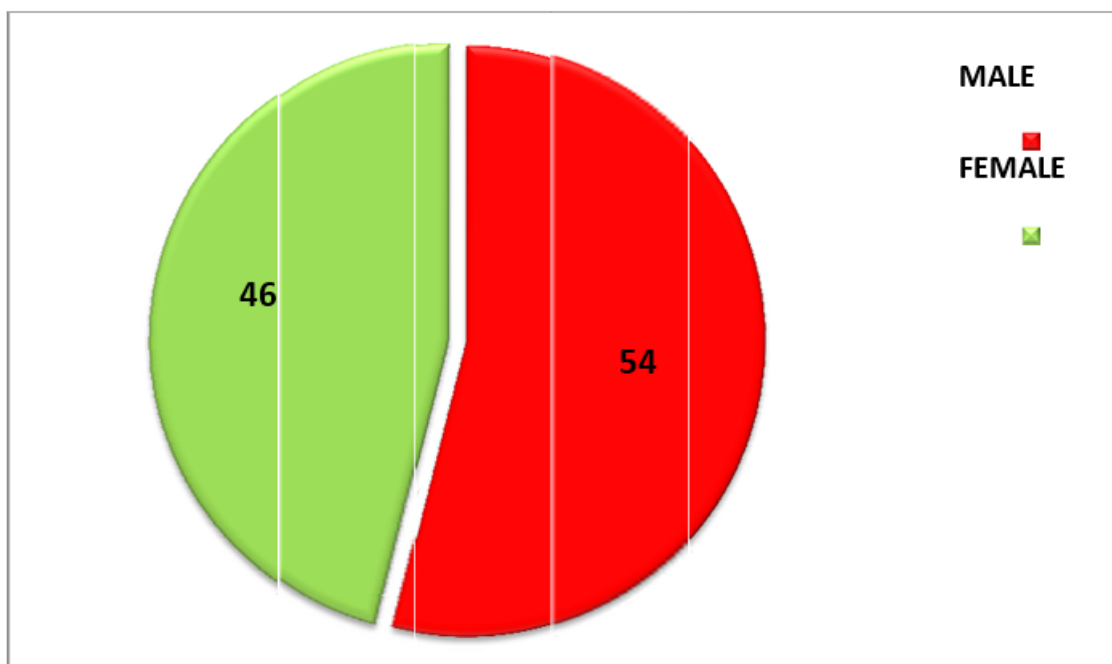


Fig 1. PIE DIAGRAM REPRESENTS GENDER WISE DISTRIBUTION PATIENTS

TABLE NO.2 AGE AND GENDER WISE DISTRIBUTION

AGE	Males	Females	Total
<20yrs	2 (3.7%)	3 (6.5%)	5 (5.0%)
20-30 yrs	18 (33.3%)	16 (34.8%)	34 (34.0%)
30-40yr	8 (14.8%)	12 (26.1%)	20 (20.0%)
40-50yr	17 (31.5%)	8 (17.4%)	25 (25.0%)
>50yr	9 (16.7%)	7 (15.2%)	16 (16.0%)
Total	54	46	100
Mean ± SD	38.32 ± 13.51	34.87 ± 15.34	37.08 ± 14.83
t-test and P-value	t = 1.436,		P = 0.142, NS

NS=

not significant, S=significant, HS=highly significant

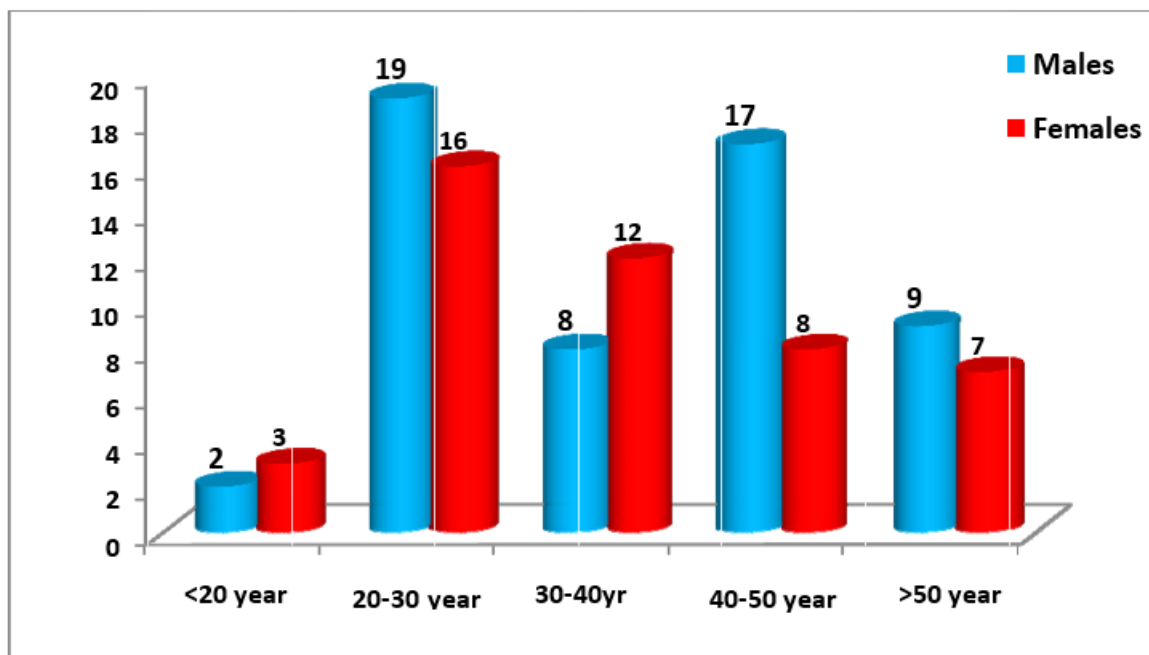


Fig 2. BAR DIAGRAM SHOWS AGE AND GENDER WISE DISTRIBUTION

TABLE NO. 3 SYMPTOMS WISE DISTRIBUTION OF PATIENTS

SYMPTOMS	MALES	FEMALES	TOTAL
PAIN	54	46	100
BLEEDING	22	20	42
CONSTIPATION	53	45	98

Defecation was painful for every single subject in this research. Subsequently, 98.0% of patients had constipation.

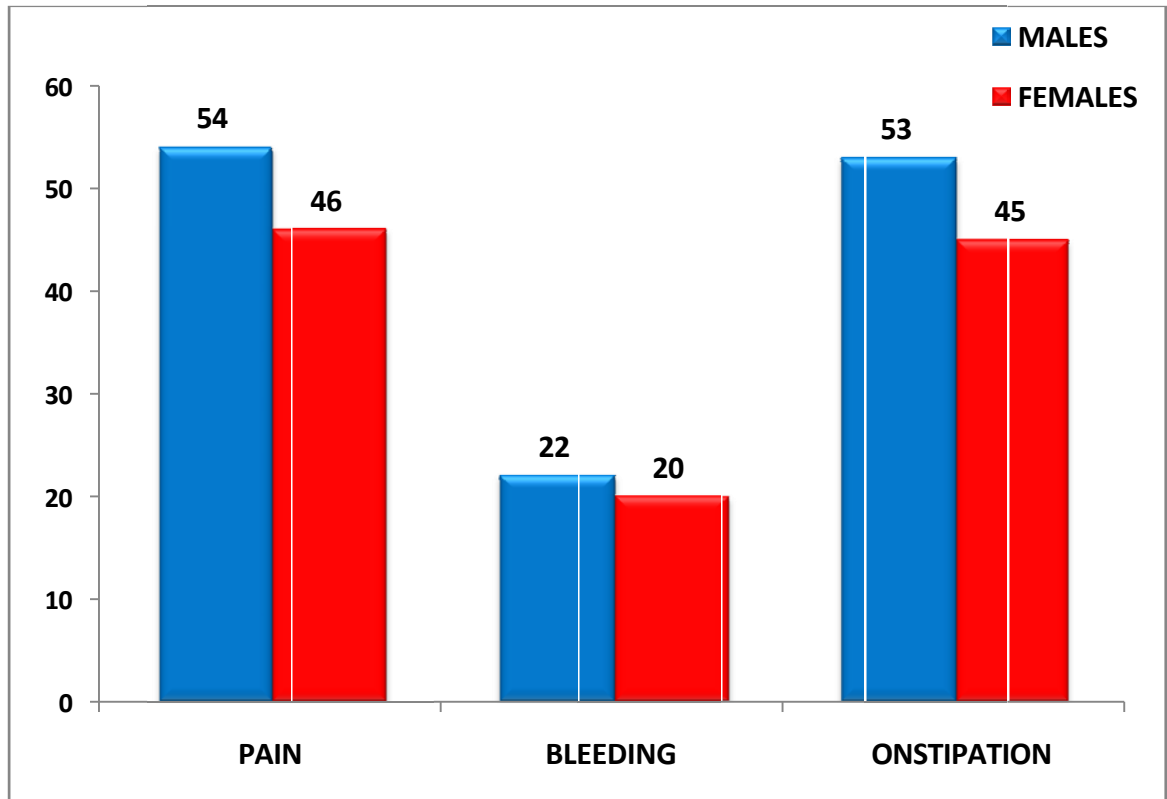


Fig 3. BAR DIAGRAM SHOWS SYMPTOMS WISE DISTRIBUTION OF PATIENTS

TABLE NO. 4 POSITION OF SENTINEL PILE

POSITION	MALES	FEMALES	TOTAL
ANTERIOR	1	1	2
ANT+POST	13	16	29
POSTERIOR	20	19	39
NO PILE	20	10	30

Study observed that; maximum number 39 (39.0%) of patient's position of sentinel pile was posterior

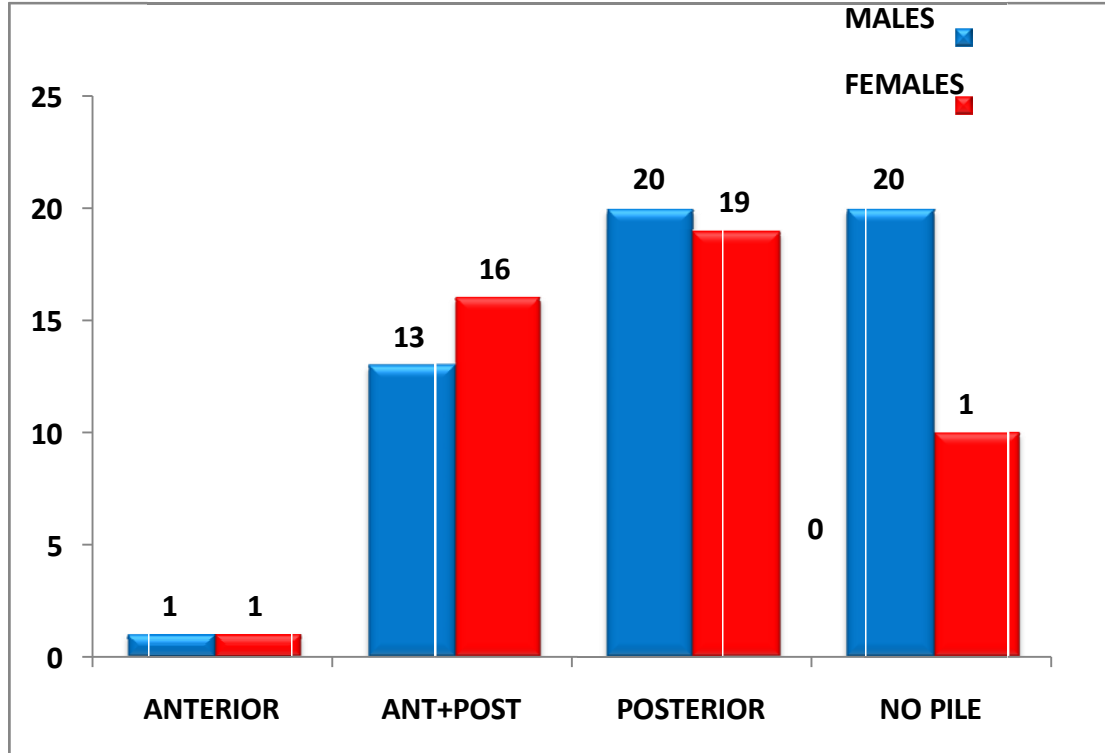


Fig 4. BARS REPRESENT POSITION OF SENTINEL PILE

TABLE NO.5: DURATION OF SYMPTOMS WISE DISTRIBUTION OF PATIENTS

DURATION	MALES	FEMALES	TOTAL
<3 MONTHS	5	4	9
3-6 MONTHS	31	21	52
6 MONTHS	18	21	39
TOTAL	54	46	100
Mean ± SD	6.53 ± 3.56	6.72 ± 3.91	6.60 ± 3.85
t-test and P-value	t = 0.581,		P = 0.864, NS

NS= not significant, S=significant, HS=highly significant

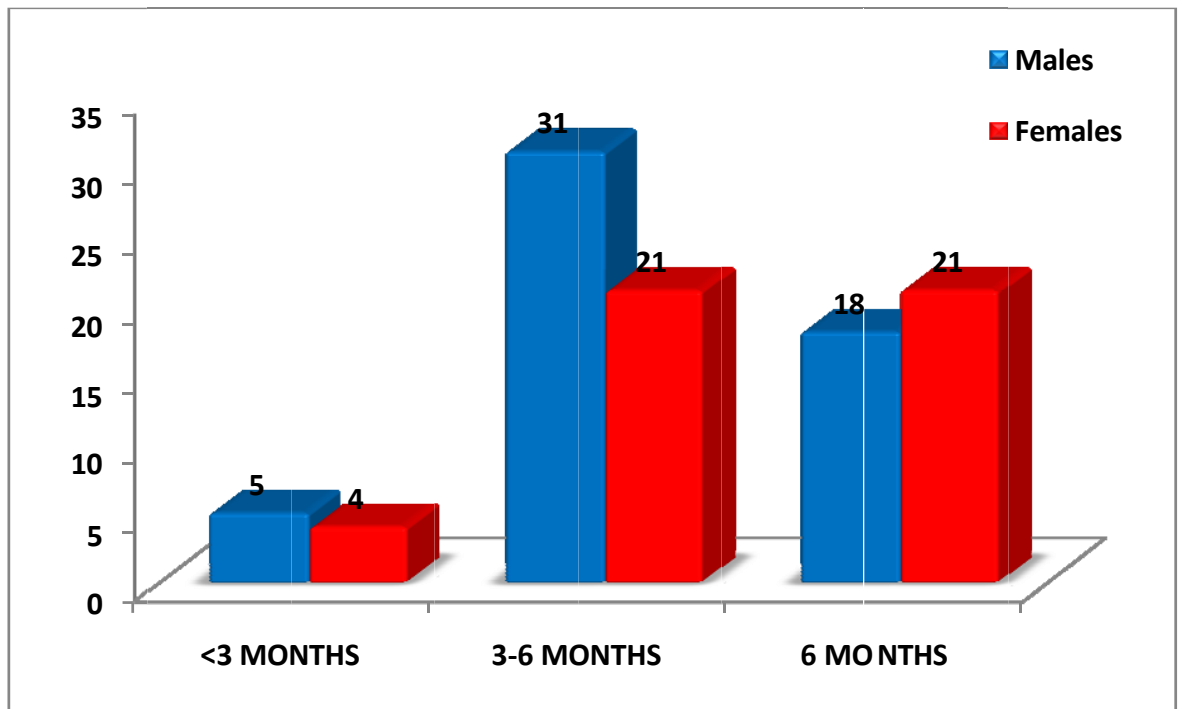


Fig 5. BAR DIAGRAM REPRESENT DURATION OF SYMPTOMS

TABLE NO. 6 IMPROVEMENT OF SYMPTOMS DURING FOLLOW UP

DURATION	PAIN	
	Yes	No
One month	61	39
Two month	51	49
Three month	20	80
Six month	25	75
X²-TEST, P-VALUE	P = 0.000	HS

NS= not significant, S=significant, **HS=highly significant**

A statistically significant difference in pain duration was seen between one month and three and six months, according to the study. (P<0.001)

t T

Fig 6. BARS REPRESENT IMPROVEMENT OF SYMPTOMS DURING FOLLOW UP

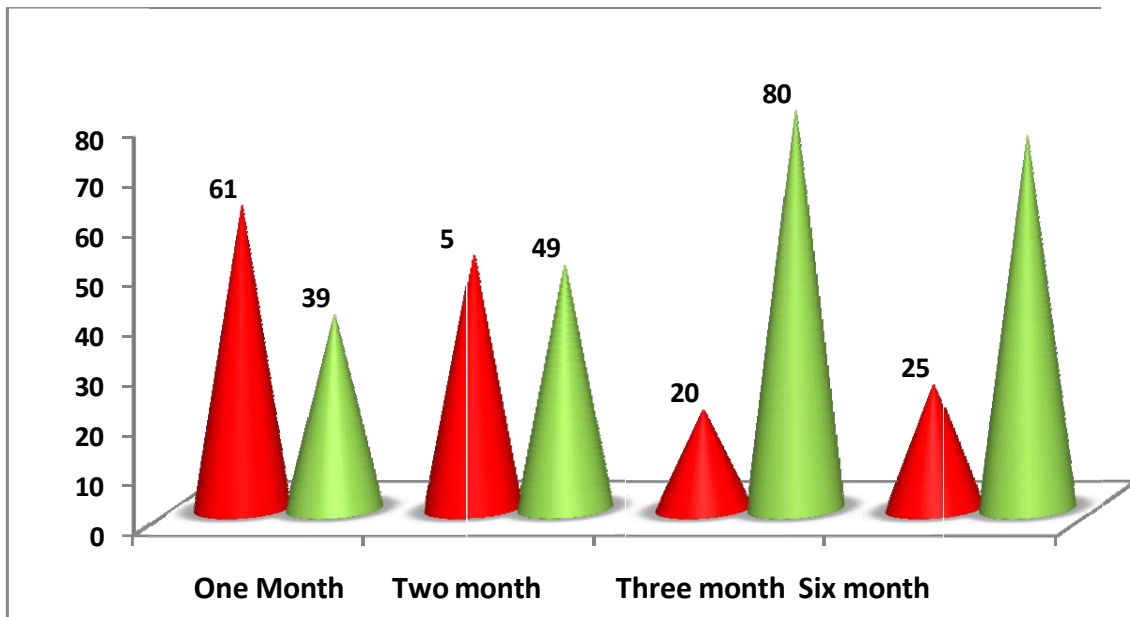


TABLE NO.7: BLEEDING DURING FOLLOWUP

DURATION	BLEEDING	
	Yes	No
One month	32	68
Two month	24	76
Three month	19	81
Six month	19	81
X ² -TEST, P-VALUE	P = 0.032	S

NS= not significant, S=significant, HS=highly significant

Study reveals that; there was statistical significant difference of duration of bleeding at one month with compare to three and six months (P<0.05)

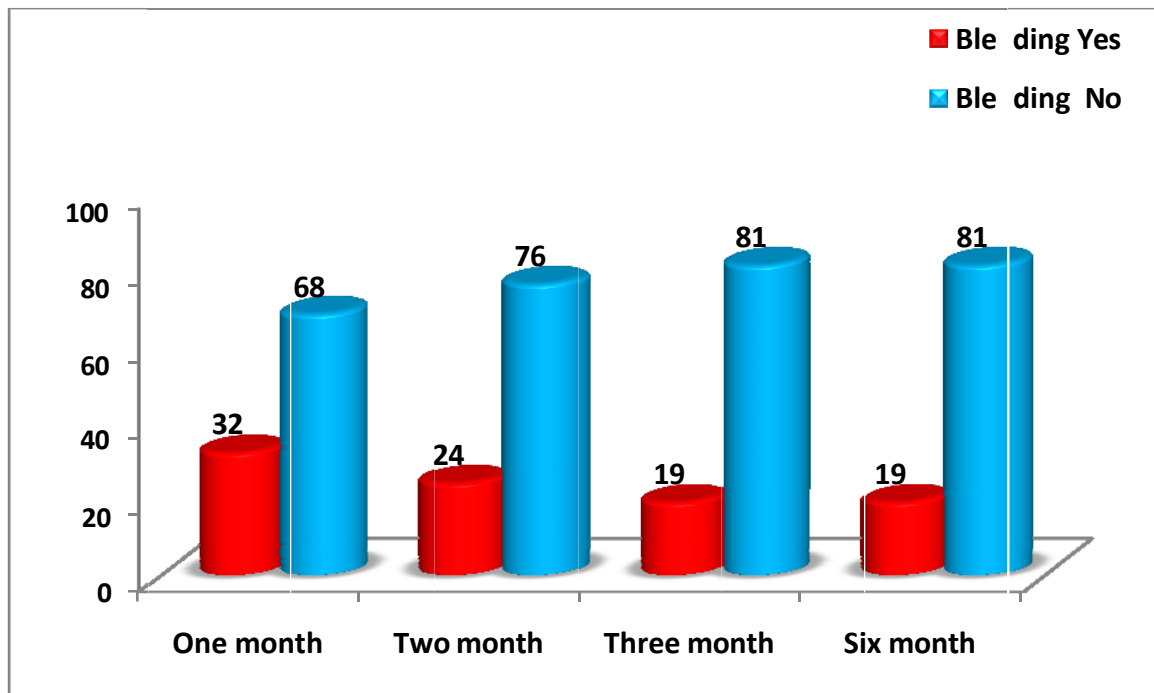


Fig 7. MULTIPLE BARS REPRESENT BLEEDING DURING FOLLOWUP

TABLE NO. 8 SPASM DURING FOLLOWUP

DURATION	SPASM	
	Yes	No
One month	41	59
Two month	26	74
Three month	19	81
Six month	19	81
X ² -TEST, P-VALUE	P = 0.005 HS	

NS= not significant, S=significant, HS=highly significant

Study reveals that; there was statistically highly significant difference of duration of spasm at one month with compare to three and six months (P<0.01)

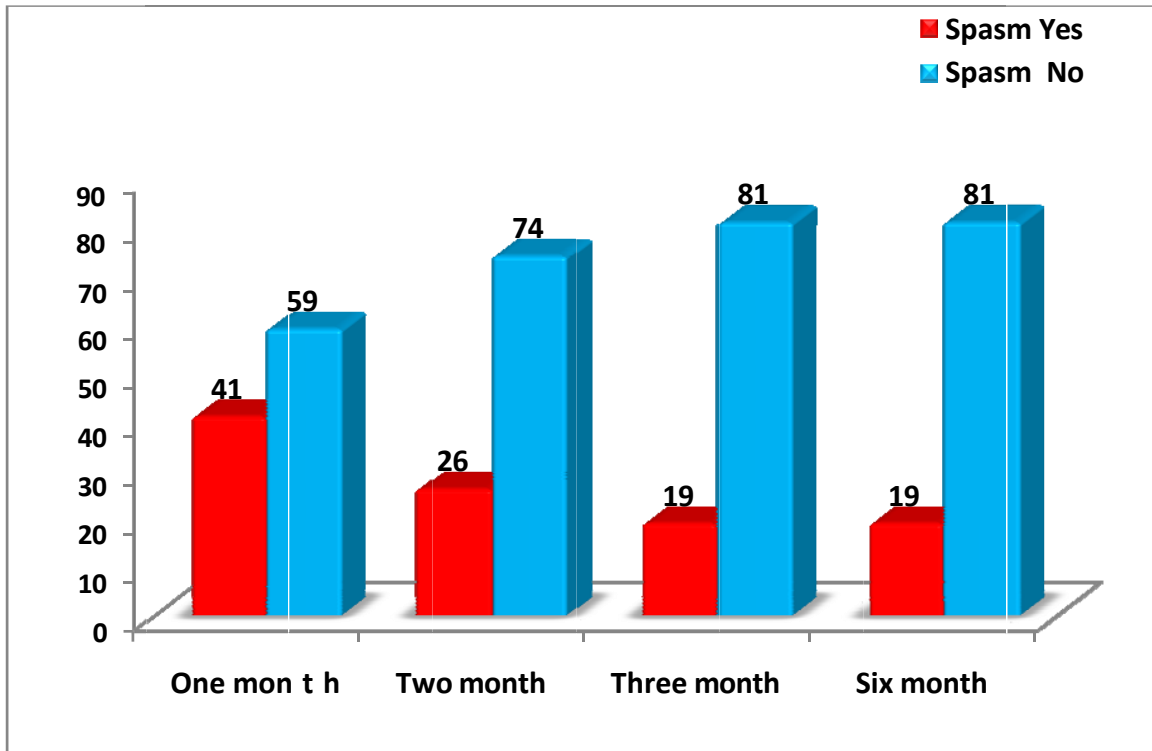


Fig 8. BAR DIAGRAM REPRESENT SPASM DURING FOLLOWUP

HEALING RATE:

Among the 100 patients who participated in our research, 76 (76.0%) had conservative treatment with local application diltiazem gel, and all of their fissures healed. Additionally, 74 (97.4%) of these patients reported no adverse effects, while 2 (92.6%) reported experiencing them. Lateral sphincterotomy was performed on 24 patients (24.0%), and all of them were successfully cured of their condition.

TABLE NO. 9 SIDE EFFECTS:

EFFECTS	Frequency	Percent
N	98	98.00%
Y	2	2.00%
Total	100	100.00%

Mild headache and local dermatitis were the only negative effects of local application of diltiazem gel that 2% of individuals in our research experienced.

DISCUSSION

A lot of people all around the globe deal with anal fissures. It generates severe morbidity and negatively impacts the quality of life. Anal fissures affect people of both sexes equally and often manifest in middle-aged or younger individuals. Although anterior fissure is more prevalent in females, it is more usually seen in the posterior position.

The formation of fissure in ano is believed to be caused by a vicious cycle of pain, spasm, and ischemia. The therapy aims to disrupt this loop. Anal dilatations and lateral internal sphincterotomies are operational management procedures. Patients requiring surgical therapy for an acute anal fissure may benefit most from a lateral sphincterotomy. There is less complexity in postoperative care, and patients recover more quickly. However, there are risks involved with the procedure, such as the possibility of persistent anal incontinence.

People in this research who were between the ages of 20 and 50 had the highest illness prevalence. The percentage of male patients was 54%. Females make up a larger proportion of anal fissure patients, according to McDonald et al. (1983)², however other research, such as the Birmingham series by Lock & Thomson et al (1977), found a minor male majority. One hundred percent of participants in our research reported discomfort during defecating. Pain and spasm were reported by 69% of patients in the study by Lock & Thomson et al. (1977). In 7% of instances, the fissure was located anteriorly, in 39% it was posteriorly located, and in 29% it was both anteriorly and posteriorly sentinel pile. However, according to research by Lock & Thomson et al. (1977), 75% of instances had a posterior fissure, whereas 14% had an anterior fissure and 3% had a lateral fissure. The researchers discovered that 38% of patients had sentinel piles. On the other hand, 76% of patients and 24% of patients with anterior fissures were identified in the research by Lund.

Patients of the feminine gender are much more likely to have anterior anal fissures. The main goal of medical and surgical therapy is to reduce the tone of the internal anal sphincter. This will promote the flow of blood to the area, which will facilitate healing. Medications including botulinum toxin, calcium channel blockers (nifedipine, diltiazem), nitrates (isosorbidedinitrate or glyceryltrinitrate), and others are used. After becoming the gold standard, lateral internal sphincterotomy and finger dilatation became the most popular surgical methods. Fissurectomy and local flap operations like the V-Y advancement flap and rotation flaps are among the other surgical treatments that have been devised. Reduced resting anal pressure is the result of smooth muscle relaxation brought about by calcium channel blockers' inhibition of slow L-type channels. In 2002, researchers at the Queens Medical Centre in the United Kingdom performed a prospective trial that confirmed that 2% Diltiazem is a safe and effective therapy for acute anal fissure in individuals who did not react to topical 0.2% GTN. While Srivastava found no statistically significant difference in the two agents' healing rates, he did find that Diltiazem cream seemed to induce less headache than GTN ointment in an identical research conducted in India. Diltiazem cream may not provide long-term benefits to all patients due to the transient nature of its effect on anal resting pressure. Results for acute anal fissure healing rates varied between trials, with 47% to 89% being the highest.

In my investigation, a healing rate of 92% was seen using 2% Diltiazem ointment. Many people find that anal dilatation is a quick and easy way to alleviate their symptoms. It tears the sphincter uncontrollably, which may disrupt continence, and it has a high recurrence rate. It is believed that lateral sphincterotomy is more successful than posterior internal sphincterotomy for fissurectomy. Presumptive lengthier wound healing time and increased frequency of disrupted continence have led to its mostly abandonment. In the past, lateral internal sphincterotomy was the standard method for treating chronic anal fissure. It is easy to do and claims to alleviate pain quickly. As a result, several surgeons recommend it to patients with persistent anal fissures. Significant pain alleviation was seen at, and 6 months of follow-up in the group treated with lateral internal sphincterotomy ($p=0.00001$) in our research. A study conducted by Ohet al. found that 95% of patients who had an open lateral internal sphincterotomy experienced rapid pain reduction. After two weeks, 92% of patients reported pain reduction with Ho and Ho 12. Within 6 months, 92% of patients in our surgical therapy group had fully healed fissures. The 84% healing rate that Hananal and Gordon recorded after 4 weeks was increased to 94.4 % after 8 weeks. Different writers have documented varying degrees of incontinence, with women often reporting the most cases. Fecal incontinence did not occur in any of the participants undergoing surgical therapy in our research. Incontinence was also reported in 8–30% of individuals in another study. Accordingly, our current research lends credence to the many literatures that provide credence to the conventional trials comparing lateral internal sphincterotomy with 2% diltiazem ointment for the treatment of acute anal fissure.

V. CONCLUSION

Sphincterotomy Utilizing a Topical 2% Chemical Agent When treating chronic anal fissure, diltiazem should be considered initially. Patients who have recurrence after previous pharmaceutical therapy has failed might be considered for internal sphincterotomy. The risk of complications such as incontinence, which can occur as a result of the procedure, is less than 1%.

Conservative treatment alone, including increasing fiber consumption (e.g., psyllium), increasing bulk and stool transit time, and warm soaking of the perineum (sitz baths), will cure about half of the patients with acute anal fissures. total The somatoanal reflex is thought to be responsible for the internal anal sphincter relaxing after a hot bath.

SUMMARY

As a consequence of anatomically correcting the etiological component of elevated sphincter pressure, lateral sphincterotomy heals chronic fissure in ano and provides full symptom relief to the majority of patients. Minimal complications are associated with lateral sphincterotomy. In terms of sphincter spasm and fissure healing, Lateral Sphincterotomy is superior to diltiazem ointment use for the treatment of chronic fissure in ano. Nevertheless, a considerable number of patients get positive outcomes. Acute fissures may be well managed and chronicity can be prevented with the use of diltiazem. Therefore, for those who would rather not have surgery and would rather get medicinal treatment, diltiazem therapy is an excellent choice.

REFERENCES

1. Nivatvongs S, Stern HS, Fryd DS. The length of the anal canal. *Dis Colon Rectum* 1982;24:600–601.
2. Milligan ETC, Morgan CN. Surgical anatomy of the anal canal: with special reference to anorectal fistulae. *Lancet* 1934; 2:1150–1156.
3. Parks AG. Pathogenesis and treatment of fistula-in-ano. *Br Med J* 1961; 1:463–469.
4. MorrenGI, Beets-Tan RGH, van EngelshovenJma. Anatomy of the anal canal and perianal structure as defined by phased-array magnetic resonance imaging. *Br J Surg* 2001; 88:1506–1512.
5. Principles and Practice of Surgery for the Colon, Rectum, and Anus pg 8Third Edition Philip H. Gordon, SanthatNivatvongsInforma health careUSA 2007.
6. Cook TA, Brading AF, Mortensen NJ. The pharmacology of the internal anal sphincter and new treatments of anorectal disorders. *Aliment Pharmacol Ther.* 2001;15:887–898.
7. Seow-Choen F, Ho JMS. Histoanatomy of anal glands. *Dis Colon Rectum*1994;37:1215–1218.
8. Garavoglia M, Borghi F, Levi AC. Arrangement of the anal striated musculature. *Dis Colon Rectum* 1993; 36:10–15.
9. Brin MF. Botulinum toxin: chemistry, pharmacology, toxicity, and immunology. *Muscle Nerve Suppl.* 1997;6:S146–S168.
10. Cui M, Khanijou S, Rubino J, Aoki KR. Subcutaneous administration of botulinum toxin A reduces formalin-induced pain. *Pain.* 2004;107:125–133.